

# Percutaneous Controlled Radiofrequency Trigeminal Rhizotomy for the Treatment of Idiopathic Trigeminal Neuralgia: 25-year Experience with 1600 Patients

Yücel Kanpolat, M.D., Ali Savas, M.D., Ph.D.,  
Ahmet Bekar, M.D., Caglar Berk, M.D.

Department of Neurosurgery (YK, AS, CB), Ankara University School of Medicine, Ankara, Turkey, and Department of Neurosurgery (AB), Uludag University School of Medicine, Bursa, Turkey

**OBJECTIVE:** The objective of this study was to evaluate the effectiveness of percutaneous, controlled radiofrequency trigeminal rhizotomy (RF-TR). The outcome of 1600 patients with idiopathic trigeminal neuralgia after RF-TR was analyzed after a follow-up period of 1 to 25 years.

**METHODS:** A total of 1600 patients with idiopathic trigeminal neuralgia underwent 2138 percutaneous radiofrequency rhizotomy procedures between 1974 and 1999. Sixty-seven patients had bilateral idiopathic trigeminal neuralgia, and 36 of them were treated with bilateral RF-TR; 1216 patients (76%) were successfully managed with a single procedure, and the remainder were treated with multiple procedures. Benzodiazepines and narcotic analgesics were used for anesthesia because patient cooperation during the procedures was essential so that the physician could create selective, controlled lesions.

**RESULTS:** The average follow-up time was  $68.1 \pm 66.4$  months (range, 12–300 mo). Acute pain relief was accomplished in 97.6% of patients. Complete pain relief was achieved at 5 years in 57.7% of the patients who underwent a single procedure. Pain relief was reported in 92% of patients with a single procedure or with multiple procedures 5 years after the first rhizotomy was performed. At 10-year follow-up, 52.3% of the patients who underwent a single procedure and 94.2% of the patients who underwent multiple procedures had experienced pain relief; at 20-year follow-up, 41 and 100% of these patients, respectively, had experienced pain relief. No mortalities occurred. After the first procedure was performed, early pain recurrence (<6 mo) was observed in 123 patients (7.7%) and late pain recurrence was observed in 278 patients (17.4%). Complications included diminished corneal reflex in 91 patients (5.7%), masseter weakness and paralysis in 66 (4.1%), dysesthesia in 16 (1%), anesthesia dolorosa in 12 (0.8%), keratitis in 10 (0.6%), and transient paralysis of Cranial Nerves III and VI in 12 (0.8%). Permanent Cranial Nerve VI palsy was observed in two patients, cerebrospinal fluid leakage in two, carotid-cavernous fistula in one, and aseptic meningitis in one.

**CONCLUSION:** Percutaneous, controlled RF-TR represents a minimally invasive, low-risk technique with a high rate of efficacy. The procedure may safely be repeated if pain recurs. (*Neurosurgery* 48:524–534, 2001)

**Key words:** Pain, Percutaneous procedures, Radiofrequency thermocoagulation, Rhizotomy, Trigeminal nerve, Trigeminal neuralgia

Idiopathic trigeminal neuralgia (ITN) is the most common form of cranial neuralgia. Trigeminal neuralgia (TN) is a painful condition of the face characterized by paroxysmal lancinating, shocklike pain confined to the somatosensory distribution of the trigeminal nerve. ITN occurs with a mean annual incidence of four or five patients per 100,000 population (23, 49, 85). The cause of ITN has not been explained fully, although compression of the trigeminal nerve by a vascular structure is the most common finding during exploration of

the cerebellopontine angle, and pain is usually relieved after the patient has undergone microvascular decompression (MVD) (20, 26, 31, 33, 38).

Since the first scientific publication on TN by John Fothergill in 1773 (30, 66, 74, 84), a variety of treatments have been advocated and practiced by surgeons throughout the world. Various safe and effective surgical treatment alternatives for TN now exist, such as percutaneous, controlled radiofrequency trigeminal rhizotomy (RF-TR) (2, 3, 12, 18, 35,

## Radiofrequency Rhizotomy in Trigeminal Neuralgia

42, 52, 55–57, 63–65, 68, 69, 72, 73, 75), MVD (7, 16, 32, 43, 50, 89), glycerol rhizolysis (6, 9, 10, 21, 25, 28, 48, 54, 71, 76, 86), and percutaneous balloon microcompression (45, 46, 51, 53). Certain practitioners consider several of these surgical procedures to be the treatment of choice for TN (4, 22).

Our group, which has been involved in treatment of TN for more than 25 years, used a single treatment method (RF-TR) for the first 10 years of our practice. For the last 15 years, however, we have been using all contemporary and established surgical techniques to manage patients with TN. In this study, we retrospectively analyze data from 1974 to 1999 from 1600 patients with ITN who underwent percutaneous controlled RF-TR.

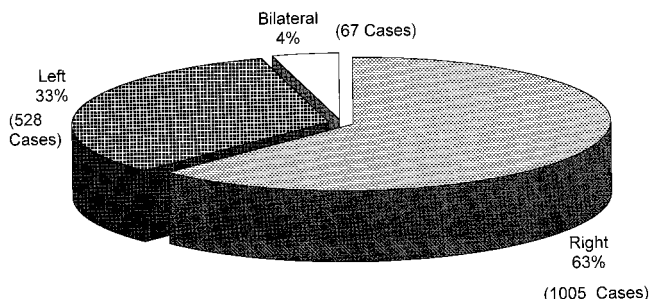
### PATIENTS AND METHODS

#### Patient population

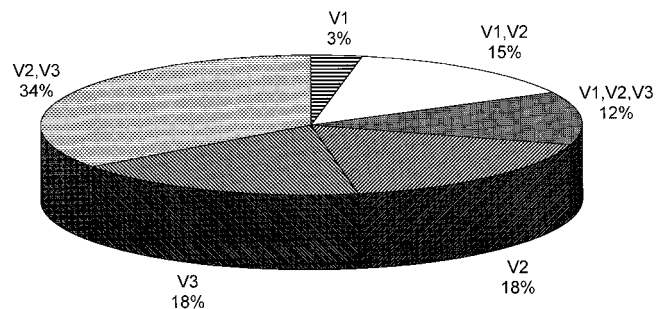
Between 1974 and 1999, 1724 patients underwent 2310 RF-TR procedures at the Department of Neurosurgery, Ankara University. A total of 1600 idiopathic TN cases constituted the majority of patients, whereas 72 patients had symptomatic TN, 38 had atypical facial pain, 10 had cluster headaches, and 4 had trigeminal neuropathic pain.

Of the patients with ITN, 834 (52.1%) were women and 766 (47.9%) were men. The patients ranged in age from 15 to 99 years (mean,  $56.83 \pm 13$  yr). Other clinical characteristics of these patients are shown in *Figures 1* and *2* as well as in *Table 1*. Sixty-seven patients had bilateral TN, and 36 of them underwent bilateral RF-TR. The majority of the patients (421) had experienced TN for less than 24 months, whereas 36 patients had experienced TN for more than 20 years (mean, 6.5 yr).

In this study, carbamazepine was the principal medication used for medical therapy before surgical treatment. Of the 1600 patients, 1366 (86.4%) reported that carbamazepine was inadequate for pain control, although their pain had responded well at earlier stages of their disease, and 214 (13.4%) were intolerant to carbamazepine.



**FIGURE 1.** Percentage of localization of pain in 1600 patients with TN.



**FIGURE 2.** Distribution of pain localization in 1600 patients with TN.

**TABLE 1.** Interventions Performed before Radiofrequency Trigeminal Rhizotomy Procedures in 1600 Patients

Procedures	No. of Patients
Peripheral alcohol injection	227
Infraorbital neurectomy	136
Frazier operation	44
Microvascular decompression	10
Glycerol rhizolysis	9
Acupuncture	7
Dandy operation <sup>a</sup>	7
Total	440

<sup>a</sup> Dandy (20).

#### Patient selection, management criteria, data acquisition, and outcome parameters

Patients with electric shock-like, paroxysmal pain without pathological findings on cranial magnetic resonance imaging or computed tomographic scans were accepted as having ITN. Most of the patients had been evaluated by cranial magnetic resonance imaging preoperatively during the previous 15 years to exclude any lesion or tumor in the pontocerebellar angle, petrous apex, cavernous sinus, or cranial base. A majority of the patients who were diagnosed with ITN had no abnormal neurological findings related to the trigeminal nerve. Electrocardiograms and chest x-rays were routinely obtained and evaluated by an anesthesiologist before surgery. Patients who were older, patients who did not want MVD, and patients with poor medical status were selected for this procedure. Although we do not enforce a strict age limit for this surgery, we usually recommend that patients older than 50 years of age undergo RF-TR. The procedure was repeated if complete pain relief was not achieved or if pain recurred. Subsequent procedures in pain recurrence are especially indicated in patients with early pain recurrence (within 1 wk after undergoing RF-TR), in patients with poor medical status, and in patients with pain refractory to carbamazepine treatment up to a dose of 800 mg per day.

We reviewed surgical records retrospectively. All data available from previous records were processed and stored in

a specially designed computer database (FileMaker Pro 2.1; Claris Corp., Cupertino, CA). The data were matched with the data acquired from a questionnaire that provided information about the degree and duration of pain relief, the need for further therapy, the presence of surgical sequelae, and a subjective assessment of the patients' overall degree of improvement—that is, complete pain relief, partial satisfactory pain relief, partial unsatisfactory pain relief, no change, and worse. Partial satisfactory pain relief meant that recurrent pain was less severe than preoperatively; that pain could be controlled with medication; and that there was no need for a subsequent RF-TR procedure. Complete pain relief meant that the patient took no medication and experienced no pain; only data for patients in the latter category are shown in the results. The profile of pain-free survival after undergoing the first RF-TR during the follow-up time was calculated according to the Kaplan-Meier method (Fig. 3) (37).

### Operative technique

The majority of patients underwent RF-TR performed by the senior author (YK) or by his colleagues under his supervision. Blood pressure recordings of patients were made at 5-minute intervals; we routinely and continuously assessed blood oxygen saturation and cardiac function. RF-TR was performed while the patient was sedated, and analgesia was administered by a neuroanesthesiologist. Intravenous slow injection of a combination of alfentanil and midazolam usually brought about the desired level of analgesia and sedation throughout the procedure. The dose of anesthetic medication was gradually increased to provide a considerable level of anesthesia so that patients experienced minimal pain. The anesthesia was administered at a level that gave comfort to both the patient and surgeon during the electrical test stimulation and lesioning procedure, allowing patient cooperation as the surgeon performed controlled and selective lesioning. Because of the vagal reflex, atropine was the primary drug used

for bradycardia, especially during penetration of the foramen ovale; nifedipine provided sublingually was the most frequently used antihypertensive agent in patients with chronic hypertension. Nitroglycerine dermal patches were applied to patients who were predisposed to cardiac ischemia and acute hypertension. General anesthesia was never used and is not recommended, because patient cooperation is essential to this procedure.

The RF-TR needle (TIC kit or Tew kit; Radionics, Inc., Burlington, MA) was inserted toward the temporal fossa as described elsewhere (56, 70). At the beginning of the procedure, x-rays of the patient in the submentovertebral position provided information that allowed us to place the needle around the foramen ovale; the needle was then inserted through the foramen. Lateral x-rays were obtained to ensure that the tip of the needle did not reach beyond the petroclival junction. The desired target area was the preganglionic (retrogasserian) fibers of the gasserian ganglion, which is described as the junction of the lines joining the clivus and petrous apex radiologically; however, the mainstay of precise localization is the careful stimulation process.

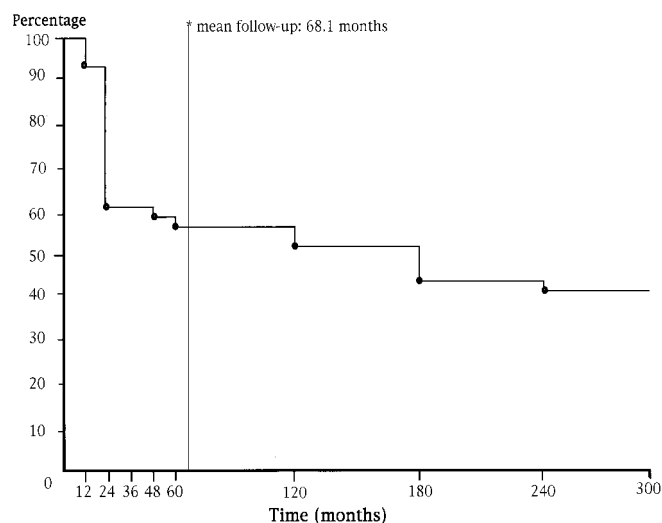
We used thermistor electrodes (TIC kit or TEW kit). In principle, straight electrodes were preferred for third-branch neuralgia, and curved electrodes were preferred for the first- or second-branch neuralgia. Because selective RF-TR of the desired branch of the trigeminal nerve is essential, we confirmed localization within the nerve by electrical stimulation at 0.2 to 1 V (50 Hz, 0.2 ms). Lesions were made at a temperature of 55 to 70°C. The preferred temperature for the initial or test lesion was 55°C; a temperature of 70°C was never exceeded during the procedure. The ciliary reflex (masseter function) affected facial areas after stimulation, and lesioning was continuously and cautiously monitored during RF-TR. The procedure was completed if adequate hypalgesia was achieved in the targeted branch and if pain could not be triggered as it had been preoperatively. The average number of lesions per procedure was four.

The patients were typically discharged on the day of surgery. Overnight hospitalization was recommended in patients with poor medical status to observe pain alleviation and vital functions after the procedure was completed. All medications previously provided for pain control were discontinued after the patient had undergone RF-TR.

### RESULTS

A total of 2138 RF-TR procedures were performed on 1600 patients. Overall, 1216 patients (76%) were managed with a single treatment and 384 patients (24%) with multiple RF-TR procedures. RF-TR was performed twice in 275 patients, three times in 79, four times in 19, five times in 8, and six times in 3.

Acute pain relief was experienced by 1561 patients (97.6%) after RF-TR was performed, and this finding was accepted as the initial success rate of RF-TR. Early (<6 mo) pain recurrence was observed in 123 patients (7.7%), whereas late (>6 mo) recurrence was reported in association with 278 patients (17.4%). The overall pain recurrence rate was 25.1% during an



**FIGURE 3.** Kaplan-Meier curve for pain-free survival after a single RF-TR procedure (1216 patients).

average follow-up period of 68.1 ± 66.4 months (range, 12–300 mo).

In 719 patients (44.9%) followed for 5 years, 57.7% experienced complete pain control after a single RF-TR was performed; the pain control rate increased to 92% with multiple RF-TR procedures. In 365 patients (22.8%) followed for 10 years, 52.3% reported complete pain control after undergoing a single RF-TR procedure, and 94.2% reported pain control with a single RF-TR procedure, multiple RF-TR procedures, or both. Thirty-nine patients (2.4%) were followed for more than 20 years, with 41% achieving complete pain control from a single RF-TR procedure (Table 2; Fig. 3). Ninety-six patients (6%) required medication during the follow-up period, and these patients were not included in the successful treatment group.

After undergoing the first RF-TR procedure, 773 patients (68.2%) experienced selective pain control—that is, pain relief with hypalgesia obtained in the same division or divisions of the trigeminal nerve experiencing neuralgia—and 360 patients (31.7%) experienced nonselective pain control—that is, hypalgesia in the other branches as well. A second RF-TR procedure resulted in 172 patients (65.6%) with selective pain control and 90 patients (34.4%) with nonselective pain control. Overall, 66.2% experienced selective and 33.9% experienced nonselective pain control.

**Side effects and complications**

After undergoing RF-TR, absent or diminished corneal reflex was observed in 91 patients (5.7%) (Table 3). Among these, 10 patients (0.6% of the entire series) experienced keratitis. Masseter dysfunction was observed in 66 (4.1%) of 1600 patients, whereas only 18 (1.1%) had initial difficulty with chewing, and all improved during follow-up. Painful dysesthesia occurred in 28 patients (1.8%), resulting in anesthesia dolorosa in 12 (0.8%). Interestingly, the number of procedures did not correlate well with the occurrence of painful dysesthesia or anesthesia dolorosa, and most patients (89.2%) with these conditions had a single RF-TR procedure. One patient experienced transient nerve palsies of Cranial Nerve III, and 11 patients experienced palsies of Cranial Nerve VI. Two patients (0.13%) were left with permanent Cranial Nerve VI palsy. Two patients had proven cerebrospinal fluid leakage that resolved spontaneously within 2 days. Carotid artery puncture was encountered in 12 patients in the early years,

**TABLE 3. Complications Related to 2138 Radiofrequency Trigeminal Rhizotomy Procedures in 1600 Patients**

Complications and Side Effects	Patients	
	No.	%
Anesthesia dolorosa	12	0.8
Painful dysesthesia	16	1.0
Absent corneal reflex	91	5.7
Corneal keratitis	10	0.6
Masseter paresis	48	3.0
Masseter paralysis	18	1.1
Transient cranial nerve paralysis	12	0.75
<i>Oculomotor nerve</i>	1	
<i>Abducens nerve</i>	11	
Permanent cranial nerve paralysis, abducens nerve	2	0.13
Cerebrospinal fluid leak	2	0.13
Carotid-cavernous fistula	1	0.06
Aseptic meningitis	1	0.06

with one resulting in a carotid-cavernous fistula (27). The fistula was treated with trapping via surgical ligation of the carotid artery. The patient’s pain recurred a year later and was managed again with RF-TR. Transient mean arterial blood pressure elevation to a level 50% greater than baseline measurements was observed in 19% of patients just after penetration of the foramen ovale. However, bradycardia and hypertension were manageable with drugs intraoperatively. No mortality was observed in 2138 procedures on 1600 patients.

**DISCUSSION**

TN is the most frequently occurring of the craniofacial neuralgias. ITN should be foremost in the clinician’s differential diagnosis when a patient complains of intermittent, paroxysmal pain confined to the distribution of one trigeminal nerve. The pain may be confined to an area as small as that supplied by a single branch of the nerve or spread throughout the distribution of one or more divisions of the nerve (49, 59). The features of the pain that characterize TN, other than its location, are its severity and its lancinating or shocklike quality. The pain may occur spontaneously but also may be triggered by almost any stimulus (15, 16, 30). Dandy (20) first observed TN to be caused by compression of the root entry zone of the

**TABLE 2. Long-term Results in Patients with Complete Pain Relief<sup>a</sup>**

Follow-up (mo)	No. of Patients	Single RF-TR		Single RF-TR, Multiple RF-TR, or Both	
		No.	%	No.	%
60	719	415	57.7	662	92.1
120	365	191	52.3	344	94.2
180	147	62	42.2	143	97.3
240	39	16	41.0	39	100
Total	1270	684	—	1188	—

<sup>a</sup> Long-term results were defined as results that lasted more than 60 months, with complete pain relief achieved after radiofrequency trigeminal rhizotomy (RF-TR). Pain relief was defined as complete if the patient took no medication and experienced no pain.

trigeminal nerve by vascular structures (1, 20, 38). For patients in whom medical treatment fails to control pain, many procedures have been devised in an attempt to alleviate ITN—for example, RF-TR, MVD, glycerol rhizolysis, and percutaneous trigeminal balloon microcompression (28, 45, 50, 51, 68, 69, 72, 73, 75). Large series documenting a considerable number of patients have been published during the last 30 years. As expected, most authors have advocated the superiority of the technique that they used (32, 50, 63, 80).

Because microvascular compression is a cause of ITN, MVD may be considered the most appropriate treatment method (5, 50). The initial success rate has been reported as 92.7% in larger published series. Overall mortality from MVD has been reported as 0.7% (78). The mean reported time to recurrence was 1.9 years, with 47 to 75% of recurrences in the first year, and the likelihood of recurrence thereafter was 2% per year (8, 64, 72, 78). In another series, major recurrences averaged 3.5% annually, and minor recurrences averaged 1.5% annually (17). McLaughlin et al. (50) reported cerebellar injury, hearing loss, and cerebrospinal fluid leakage as the most important complications in their MVD series with 4400 patients. In large series, cerebellar infarction, cerebrospinal fluid leakage, and pulmonary complications after MVD were observed at a rate of less than 1%. Palsies of Cranial Nerves VII and VIII were unique complications observed after MVD, however, occurring in approximately 4% of patients (78). On the other hand, the risks of this operation should never be underestimated, especially when performed by inexperienced neurosurgeons. Experienced authors reported low rates of morbidity and mortality, and early pain recurrence may be overcome by performing a second MVD (50, 89). However, performing a second operation after the patient has experienced late pain recurrence may be challenging (19, 80, 83). The absence of vascular compression during exploration of the cerebellopontine angle is one of the critical issues. Approximately 15% of patients may not have a significant vascular compression, or adequate decompression may not be achieved safely in them (72). Patients with anomalies of the posterior fossa and bony variations present another serious problem during exploration (32).

Glycerol rhizolysis was first described by Håkanson (28) and is especially valuable in patients with pain localized in the first branch of the trigeminal nerve (6, 9, 10, 21, 25, 28, 47, 48, 54, 61, 71, 76). Although surgeons were initially optimistic about the procedure, glycerol rhizolysis is a destructive procedure, and its success rate is not high. The highest rate of pain recurrence was 54% with glycerol rhizolysis in a series with a mean follow-up period of 4 years (72). In our opinion, glycerol rhizolysis is indicated in patients with pain localized to the first branch; it is also indicated if MVD or RF-TR fails or cannot be performed.

Percutaneous trigeminal balloon microcompression is an effective way to treat ITN. Lichtor and Mullan (13, 14, 45, 53) popularized this method. The literature includes reports that the initial success rate of this procedure averages 92.1%. The recurrence rates from percutaneous trigeminal balloon microcompression series are approximately 25% at 3 years (13, 78). Autonomic changes such as bradycardia and blood pressure

changes may occur during needle placement and compression with the balloon (78). The foramen ovale may not be large enough for the needle in 1% of patients (72). In a series of 236 patients who underwent trigeminal balloon microcompression, detectable hypesthesia was observed in 61% of patients and loss of the corneal reflex in only one patient, but no anesthesia dolorosa was observed (13). Serious problems related to masseter paresis may be observed in 10% of patients during balloon microcompression (78), and in this procedure, the recovery time for the masseter paresis seems to have been longer than that found after RF-TR (13, 14, 45, 78).

Both glycerol rhizolysis and balloon microcompression require no patient cooperation during the procedures; the latter procedure may even be done while the patient is under general anesthesia. Thus, these procedures may be performed by neurosurgeons who do not treat a large number of patients with TN. However, RF-TR involves considerable experience, skill, and judgment in establishing the lesion in a selected branch of the trigeminal nerve (4, 13, 22, 45).

External beam radiosurgery is a new treatment modality, the role of which remains unclear (40, 41, 87, 88). No data are available from large series with long-term follow-up. This is also a destructive procedure, and no firm criteria for lesion parameters exist. If pain recurs, the effectiveness and indication criteria of subsequent procedures—as well as the number of subsequent procedures—are unknown. In our opinion, the entry zone of the trigeminal nerve is a good target, but radiosurgery cannot provide standard criteria for this as a treatment modality. We think that this method is indicated only for patients with TN that is refractory to surgery.

RF-TR is a treatment method that was developed to allow the surgeon to make controlled, selective lesions in the ganglion via a percutaneous approach (69, 80, 84). The principle of this treatment is the thermal effect (55–70°C) of radiofrequency on pain fibers (24, 44). Experimental studies have shown that small, unmyelinated pain fibers are irreversibly affected at temperatures of 55 to 70°C (34, 67, 82).

One of the most important steps of the RF-TR procedure is the penetration of the foramen ovale (72, 77, 79, 81). The trajectory of the needle at the entrance to the foramen ovale is important. The ideal penetration zone of the foramen ovale lies at the posteromedial border of the foramen. One can manipulate the electrode to its final target to make a selective lesion much more easily. Improper penetration may increase the risk of an iatrogenic carotid-cavernous fistula, and penetration of the superior orbital fissure may lead to orbital damage and even blindness (27, 62). For the first 5 years of our practice, we used cordotomy needles (Rosomoff kit; Radionics) to perform RF-TR. We then began to use TIC (with a 5-mm open tip) and Tew electrodes. Initially, we were trying to enter through the foramen ovale on the first attempt; however, we noticed that this approach led to more complications attributable to puncturing and thus to failure of the RF-TR procedure. Now we prefer to introduce the needle after examining its position around the foramen ovale on x-rays obtained while the patient is in the submentovertebral position. In addition, lesions located on the periphery of Cranial Nerve V cause treatment failure and early pain recurrences; there-

fore, we prefer to make lesions in the ganglion instead of in the postganglionic nerve branches.

The most important aspect of the evaluation of RF-TR is how controlled the lesioning procedure is, because controlled lesioning is the primary difference between RF-TR and other percutaneous procedures. Thus, this procedure requires considerable expertise. There is no way to predict or to control the degree and extent of lesioning in methods such as peripheral alcohol blocks, glycerol rhizolysis, and balloon microcompression. Radiofrequency systems facilitate fully controlled, selective lesioning. The surgeon must allow time for cooperation with the patient during both stimulation and lesioning. This is not as difficult as it is thought to be, especially with the help of smooth sedation and analgesia (11). We formerly used two medication combinations intravenously to provide analgesia and sedation: diazepam and meperidine, and we used fentanyl and dehydrobenzperidol as neuroleptanesthesia. However, these medications were unsatisfactory for maintaining patient cooperation and failed to control patients' spontaneous respiration. We have found that the combination of alfentanil and midazolam is optimal for obtaining analgesia and sedation throughout the procedure. The patient may experience bradycardia and, rarely, atrioventricular block (29, 39), especially during penetration through the foramen ovale and needle manipulations. This situation can be overcome safely with the help of continuous cardiac monitoring and the meticulous effort of the attending anesthesiologist. The risk of cardiopulmonary arrest should always be kept in mind before every procedure, and safety precautions must be taken beforehand. The number and severity of the lesions can be modified according to the degree of resulting hypalgesia, changes in the ciliary reflex, and mandibular deviation after each lesion. These steps in the procedure allow controlled lesioning and thus enhance the safety and efficacy of the RF-TR procedure, and therein lies the art of the surgeon (36, 58, 60). Controlled lesioning may be difficult to perform, however, especially in older or uncooperative patients.

To our knowledge, the series we present here has the longest follow-up of any large series reported (mean follow-up, 68.1 ± 66.4 mo; range, 12–300 mo) (Table 2; Fig. 3). Our results are satisfactory when compared with other series in which patients were treated not only with RF-TR but also with other procedures such as MVD (Tables 3–5). Our pain recurrence

rate seems to be higher, but we do not think that pain recurrence, which is probably related to the lesions made at a relatively moderate temperature (≤70°C), is a serious event when compared with the risk of painful dysesthesia or anesthesia dolorosa, which may be results of extreme lesioning. Hypalgesia should be considered not a complication but a side effect of this procedure, because successfully treated patients almost always experience mild or moderate hypalgesia or hypesthesia. Keratitis as a result of corneal anesthesia and anesthesia dolorosa are the most important complications of lesioning at high temperatures or in uncooperative patients. In our series, the rate of anesthesia dolorosa was 0.8%, the absence of corneal reflex rate was 5.7%, and the keratitis rate was 0.6% (Tables 3 and 5). Keratitis is an especially important risk for patients who live in rural areas, where medical and ophthalmological services are not easily accessible. The most critical period for the risk of keratitis in patients with an absent corneal reflex is the first month after undergoing RF-TR; during this time, these patients should be observed frequently, and safety precautions against conjunctivitis should be taken. Unilateral masseter weakness causes patients no serious difficulties in activities of daily living and subsides in 2 months. Patients with bilateral ITN can be treated with RF-TR. No major problem was observed in the 36 patients we treated with bilateral RF-TR (we treated 67 patients with bilateral ITN). Extreme bilateral denervation, however, may cause severe masticator dysfunction due to motor and sensory deficits; therefore, controlled lesioning of the second and third branches under moderate temperature is recommended if the lesions are made bilaterally (69). The two most important complications are keratitis and anesthesia dolorosa, which can be observed after RF-TR. In our opinion, these complications can be avoided or reduced to a minimum with controlled, selective lesioning.

Among the destructive procedures, RF-TR seems to be the most efficient way to treat ITN; however, the procedure greatly depends on the experience of the neurosurgeon, as in MVD (74). The rate of pain relief with this procedure is directly related to patient selection, localization and type of pain, and strategy for intervention. The most important aspect of RF-TR is its safety and efficacy as a controlled procedure, which is provided with the cooperation of the patient under sedation and analgesia during the procedure.

**TABLE 4. Long-term Results after Radiofrequency Trigeminal Rhizotomy for Treatment of Idiopathic Trigeminal Neuralgia in Different Series<sup>a</sup>**

Series (Ref. No.)	No. of Cases	Initial Pain Relief (%)	Follow-up (yr)	Long-term Recurrence (%)
Siegfried, 1981 (63)	1000	100	5.5	25
Sindou et al., 1987 (65)	609	100	1–13	7
Frank and Fabrizi, 1989 (23)	700	—	>3	25
Sweet et al., 1987 (69)	702	99	5.6	37
Broggi et al., 1990 (12)	1000	100	1–10	13
Nugent, 1991 (55)	1070	87	4.7	23
Tew and Taha, 1995 (80)	1200	98	1–21	20
Kanpolat et al. (this report)	1600	97.6	1–25	25.1

<sup>a</sup> —, not applicable.

TABLE 5. Percentages of Complications after Radiofrequency Trigeminal Rhizotomy in Different Series<sup>a</sup>

Series (Ref. No.)	Anesthesia Dolorosa	Absent Corneal Reflex	Keratitis	Dysesthesia	Masseter Weakness	Diplopia	Mortality
Siegfried, 1981 (63)	1	7	0.8	24	17	4	0
Sindou et al., 1987 (65)	25	35	20	NR	25	4	0
Frank and Fabrizi, 1989 (23)	2	9	3	23	65	0.4	0
Sweet, 1987 (69)	0.6	1	0	NR	8	0.1	0
Broggi et al., 1990 (12)	1.5	17	0.6	5	10	0.5	0
Nugent, 1991 (55)	0.5	3.5	0.4	15	26	0.2	0.2
Tew and Taha, 1995 (80)	1	6	2	20	16	1	0
Kanpolat (this report)	0.8	5.7	0.6	1	4.1	0.8	0

<sup>a</sup> NR, not reported.

## CONCLUSION

No single, standard method for the treatment of ITN exists. The most important aspect in the selection of the procedure is its suitability to the patient's status, such as age and type and distribution of pain. RF-TR is a minimally invasive and effective procedure that is especially indicated in older patients with ITN that is confined to the second and third branches. The procedure can be repeated easily if pain recurs. One remarkable advantage of RF-TR in destructive procedures is that it provides controlled, selective lesioning.

## ACKNOWLEDGMENTS

This study was presented at the annual meeting of the Congress of Neurological Surgeons, in Boston, MA, in 1999. We thank Helen Stevens for editing this article.

Received, September 13, 2000.

Accepted, November 2, 2000.

Reprint requests: Yücel Kanpolat, M.D., Inkilap Sk, 24/2 Kizilay 06640 Ankara, Turkey. Email: kanpolat@ada.net.tr

## REFERENCES

- Adams CBT: Trigeminal neuralgia: Pathogenesis and treatment. *Br J Neurosurg* 11:493-495, 1997.
- Apfelbaum RI: A comparison of percutaneous radiofrequency trigeminal neurolysis and microvascular decompression of the trigeminal nerve for the treatment of tic douloureux. *Neurosurgery* 1:16-21, 1977.
- Apfelbaum RI: Technical considerations for facilitation of selective percutaneous radiofrequency neurolysis of the trigeminal nerve. *Neurosurgery* 3:396-400, 1978.
- Apfelbaum RI: Advantages and disadvantages of various techniques to treat trigeminal neuralgia, in Rovit RL, Murali R, Jannetta PJ (eds): *Trigeminal Neuralgia*. Baltimore, Williams & Wilkins, 1990, pp 239-250.
- Apfelbaum RI: Neurovascular decompression: The procedure of choice? *Clin Neurosurg* 46:473-498, 2000.
- Arias MJ: Percutaneous retrogasserian glycerol rhizotomy for trigeminal neuralgia: A prospective study of 100 cases. *J Neurosurg* 65:32-36, 1986.
- Barker FG, Jannetta PJ, Bissonette DJ, Shields PT, Larkins MV, Jho HD: The long-term outcome of microvascular decompression for trigeminal neuralgia. *N Engl J Med* 334:1077-1083, 1996.
- Bederson JB, Wilson CB: Evaluation of microvascular decompression and partial sensory rhizotomy in 252 cases of trigeminal neuralgia. *J Neurosurg* 71:359-367, 1989.
- Bergenheim AT, Hariz MI: Influence of previous treatment on outcome after glycerol rhizotomy for trigeminal neuralgia. *Neurosurgery* 36:303-310, 1995.
- Bergenheim AT, Hariz MI, Laitinen LV: Selectivity of retrogasserian glycerol rhizotomy in the treatment of trigeminal neuralgia. *Stereotact Funct Neurosurg* 56:159-165, 1991.
- Brisman R: Analgesia and sedation during percutaneous radiofrequency electrocoagulation for trigeminal neuralgia. *Neurosurgery* 32:400-406, 1993.
- Broggi G, Franzini A, Lasio G, Giorgi C, Servello D: Long-term results of percutaneous retrogasserian thermorhizotomy for essential trigeminal neuralgia: Considerations in 1000 consecutive patients. *Neurosurgery* 26:783-787, 1990.
- Brown JA: Percutaneous treatment of trigeminal neuralgia: Advances and problems. *Clin Neurosurg* 46:455-472, 2000.
- Brown JA, Chittum CJ, Sabol D, Gouda JJ: Percutaneous balloon compression of the trigeminal nerve for treatment of trigeminal neuralgia. *Neurosurg Focus* 1:Article 4, 1996.
- Burchiel KJ: Facial pain syndromes: Practical considerations. *Clin Neurosurg* 46:435-454, 2000.
- Burchiel KJ, Slavin KV: On the natural history of trigeminal neuralgia. *Neurosurgery* 46:152-155, 2000.
- Burchiel K, Clarke H, Haglund M, Loeser JD: Long-term efficacy of microvascular decompression in trigeminal neuralgia. *J Neurosurg* 69:35-38, 1988.
- Burchiel K, Steege TD, Howe JF, Loeser JD: Comparison of percutaneous radiofrequency gangliolysis and microvascular decompression for the surgical management of tic douloureux. *Neurosurgery* 9:111-119, 1981.
- Cho DY, Chang CG, Wang YC, Wang FH, Shen CC, Yang DY: Repeat operations in failed microvascular decompression for trigeminal neuralgia. *Neurosurgery* 35:665-670, 1994.
- Dandy WE: Concerning the cause of trigeminal neuralgia. *Am J Surg* 24:447-455, 1934.
- Dieckmann G, Bockermann V, Heyer C, Henning J, Roesen M: Five-and-a-half years' experience with percutaneous retrogasserian glycerol rhizotomy in treatment of trigeminal neuralgia. *Appl Neurophysiol* 50:401-413, 1987.
- Fraioli B, Esposito V, Guidetti B, Cruccu G, Manfredi M: Treatment of trigeminal neuralgia by thermocoagulation, glycerolization, and percutaneous compression of the gasserian ganglion and/or retrogasserian rootlets: Long-term results and therapeutic protocol. *Neurosurgery* 24:239-245, 1989.

23. Frank F, Fabrizio AP: Percutaneous surgical treatment of trigeminal neuralgia. *Acta Neurochir (Wien)* 97:128–130, 1989.
24. Frigyesi TL, Siegfried J, Broggi G: The selectivity vulnerability of evoked potentials in the trigeminal sensory root to graded thermocoagulation. *Exp Neurol* 49:11–21, 1975.
25. Fujimaki T, Fukushima T, Miyazaki S: Percutaneous retrogasserian glycerol injection in the management of trigeminal neuralgia: Long-term follow-up results. *J Neurosurg* 73:212–216, 1990.
26. Gardner WJ: Trigeminal neuralgia. *Clin Neurosurg* 15:1–56, 1968.
27. Gokalp HZ, Kanpolat Y, Tumer B: Carotid-cavernous fistula following percutaneous trigeminal ganglion approach. *Clin Neurol Neurosurg* 82:269–272, 1980.
28. Håkanson S: Trigeminal neuralgia treated by the injection of glycerol into the trigeminal cistern. *Neurosurgery* 9:638–646, 1981.
29. Hampf G, Bowsher D, Wells C, Miles J: Sensory and autonomic measurements in idiopathic trigeminal neuralgia before and after radiofrequency thermocoagulation: Differentiation from some other causes of facial pain. *Pain* 40:241–248, 1990.
30. Harris W: An analysis of 1433 cases of paroxysmal trigeminal neuralgia (trigeminal-tic) and the end results of gasserian alcohol injection. *Brain* 63:209–224, 1940.
31. Jannetta PJ: Arterial compression of the trigeminal nerve at the pons in patients with trigeminal neuralgia. *J Neurosurg* 26:159–162, 1967.
32. Jannetta PJ: Microvascular decompression of the trigeminal nerve root entry zone, in Rovit RL, Murali R, Jannetta PJ (eds): *Trigeminal Neuralgia*. Baltimore, Williams & Wilkins, 1990, pp 201–222.
33. Jannetta PJ: Vascular compression is the cause of trigeminal neuralgia. *APS J* 2:217–227, 1993.
34. Kanpolat Y, Önel B: Experimental percutaneous approach to the trigeminal ganglion in dogs with histopathological evaluation of radiofrequency lesions. *Acta Neurochir Suppl (Wien)* 30:363–366, 1980.
35. Kanpolat Y, Avman N, Gokalp HZ, Arasil E, Özkal E, Selçuki M: Controlled radiofrequency thermocoagulation of trigeminal ganglion in the treatment of trigeminal neuralgia, hemifacial spasm, and facial neuralgia. *Acta Neurochir Suppl (Wien)* 33:511–514, 1984.
36. Kanpolat Y, Berk C, Savas A, Bekar A: Percutaneous controlled radiofrequency rhizotomy in the management of patients with trigeminal neuralgia due to multiple sclerosis. *Acta Neurochir (Wien)* 142:685–690, 2000.
37. Kaplan EL, Meier P: Nonparametric estimation from incomplete observations. *J Am Stat Assoc* 53:457–481, 1958.
38. Kaye AH: Trigeminal neuralgia: Vascular compression theory. *Clin Neurosurg* 46:499–506, 2000.
39. Kehler CH, Brodsky JB, Samuels SI, Britt RA, Silverberg GD: Blood pressure response during percutaneous rhizotomy for trigeminal neuralgia. *Neurosurgery* 10:200–202, 1982.
40. Kondziolka D, Lunsford LD, Habeck M, Flickinger JC: Gamma knife radiosurgery for trigeminal neuralgia. *Neurosurg Clin N Am* 8:79–85, 1997.
41. Kondziolka D, Perez B, Flickinger JC, Habeck M, Lunsford LD: Gamma knife radiosurgery for trigeminal neuralgia: Results and expectations. *Arch Neurol* 55:1524–1529, 1998.
42. Latchaw JP, Hardy RW, Forsythe SB, Cook AF: Trigeminal neuralgia treated by radiofrequency coagulation. *J Neurosurg* 59:479–484, 1983.
43. Lee KH, Chang JW, Park YG, Chung SS: Microvascular decompression and percutaneous rhizotomy in trigeminal neuralgia. *Stereotact Funct Neurosurg* 68:196–199, 1997.
44. Letcher FS, Goldring S: The effect of radiofrequency current and heat on peripheral nerve action potential in the cat. *J Neurosurg* 24:42–47, 1968.
45. Lichtor T, Mullan JF: A 10-year follow-up review of percutaneous microcompression of the trigeminal ganglion. *J Neurosurg* 72:49–54, 1990.
46. Lobato RD, Rivas JJ, Sarabia R, Lamas E: Percutaneous microcompression of the gasserian ganglion for trigeminal neuralgia. *J Neurosurg* 72:546–553, 1990.
47. Lunsford LD: Percutaneous retrogasserian glycerol rhizotomy, in Rovit RL, Murali R, Jannetta PJ (eds): *Trigeminal Neuralgia*. Baltimore, Williams & Wilkins, 1990, pp 145–164.
48. Lunsford LD, Bennett M: Percutaneous retrogasserian glycerol rhizotomy for tic douloureux: Part 1—Technique and results in 112 patients. *Neurosurgery* 14:424–430, 1984.
49. Maxwell RE: Clinical diagnosis of trigeminal neuralgia and differential diagnosis of facial pain, in Rovit RL, Murali R, Jannetta PJ (eds): *Trigeminal Neuralgia*. Baltimore, Williams & Wilkins, 1990, pp 53–77.
50. McLaughlin MR, Jannetta PJ, Clyde BL, Subach BR, Comey CH, Resnick DK: Microvascular decompression of cranial nerves: Lessons learned after 4400 operations. *J Neurosurg* 90:1–8, 1999.
51. Meglio M, Cioni B, d'Annunzio V: Percutaneous microcompression of the gasserian ganglion: Personal experience. *Acta Neurochir Suppl (Wien)* 39:142–143, 1987.
52. Mittal B, Thomas DG: Controlled thermocoagulation in trigeminal neuralgia. *J Neurol Neurosurg Psychiatry* 49:932–936, 1986.
53. Mullan S: Percutaneous microcompression of the trigeminal ganglion, in Rovit RL, Murali R, Jannetta PJ (eds): *Trigeminal Neuralgia*. Baltimore, Williams & Wilkins, 1990, pp 137–144.
54. North RB, Kidd DH, Piantadosi S, Carson BS: Percutaneous retrogasserian glycerol rhizotomy: Predictors of success and failure in treatment of trigeminal neuralgia. *J Neurosurg* 72:851–856, 1990.
55. Nugent GR: Surgical treatment: Radiofrequency gangliolysis and rhizotomy, in Fromm GH, Sessle BJ (eds): *Trigeminal Neuralgia: Current Concepts Regarding Pathogenesis and Treatment*. Boston, Butterworth-Heinemann, 1991, pp 159–165.
56. Nugent GR: Radiofrequency treatment of trigeminal neuralgia using a cordotomy-type electrode: A method. *Neurosurg Clin N Am* 8:41–51, 1997.
57. Nugent GR, Berry B: Trigeminal neuralgia treated by differential percutaneous radiofrequency coagulation of the gasserian ganglion. *J Neurosurg* 40:517–523, 1974.
58. Pelletier VA, Poulos DA, Lende RA: Functional localization in the trigeminal root. *J Neurosurg* 40:504–513, 1974.
59. Rothman KJ, Wepsic JG: Side of facial pain in trigeminal neuralgia. *J Neurosurg* 40:514–516, 1974.
60. Rovit RL: Percutaneous radiofrequency thermal coagulation of the gasserian ganglion, in Rovit RL, Murali R, Jannetta PJ (eds): *Trigeminal Neuralgia*. Baltimore, Williams & Wilkins, 1990, pp 109–136.
61. Saini SS: Retrogasserian anhydrous glycerol injection therapy in trigeminal neuralgia: Observations in 552 patients. *J Neurol Neurosurg Psychiatry* 50:1536–1538, 1987.
62. Sekhar LN, Heros RC, Kerber CW: Carotid-cavernous fistula following percutaneous retrogasserian procedures. *J Neurosurg* 51:700–706, 1979.
63. Siegfried J: Percutaneous controlled thermocoagulation of gasserian ganglion in trigeminal neuralgia: Experience with 1000 cases, in Samii M, Jannetta P (eds): *The Cranial Nerves*. Berlin, Springer-Verlag, 1981, pp 322–330.



64. Sindou M, Chiha M, Mertens P: Anatomical finding in microsurgical vascular decompression for trigeminal neuralgia: Correlations between topography of pain and site of the neuro-vascular conflict. *Acta Neurochir Suppl (Wien)* 64:125-127, 1995.
65. Sindou M, Keravel Y, Abdennebi B, Szapiro J: Neurosurgical treatment of trigeminal neuralgia: Direct approach of percutaneous method? [in French]. *Neurochirurgie* 33: 89-111, 1987.
66. Sjoqvist O: *Studies on Pain Conduction in the Trigeminal Nerve: A Contribution to the Surgical Treatment of Facial Pain*. Helsingfors, G.E. Stechert Co., 1938, pp 1-139.
67. Smith HP, McWhorter JM, Challa VR: Radiofrequency neurolysis in a clinical model: Neuropathological correlation. *J Neurosurg* 55:246-253, 1981.
68. Sweet WH: The history of the development of treatment for trigeminal neuralgia. *Clin Neurosurg* 32:294-318, 1984.
69. Sweet WH: Treatment of trigeminal neuralgia by percutaneous rhizotomy, in Youmans JR (ed): *Neurological Surgery: A Comprehensive Reference Guide to the Diagnosis and Management of Neurosurgical Problems*. Philadelphia, W.B. Saunders Co., 1990, ed 3, vol 6, pp 3888-3921.
70. Sweet WH, Wepsic JG: Controlled thermocoagulation of trigeminal ganglion and rootlets for differential destruction of pain fibers: Part 1—Trigeminal neuralgia. *J Neurosurg* 39:143-156, 1974.
71. Sweet WH, Poletti CE, Macon JB: Treatment of trigeminal neuralgia and other facial pains by retrogasserian injection of glycerol. *Neurosurgery* 9:647-653, 1981.
72. Taha JM, Tew JM Jr: Comparison of surgical treatments for trigeminal neuralgia: Reevaluation of radiofrequency rhizotomy. *Neurosurgery* 38:865-871, 1996.
73. Taha JM, Tew JM Jr: Treatment of trigeminal neuralgia by percutaneous radiofrequency rhizotomy. *Neurosurg Clin N Am* 8:31-39, 1997.
74. Taha JM, Tew JM Jr: Honored guest presentation: Therapeutic decisions in facial pain. *Clin Neurosurg* 46:410-431, 2000.
75. Taha JM, Tew JM Jr, Buncher CR: A prospective 15-year follow up of 154 consecutive patients with trigeminal neuralgia treated by percutaneous stereotactic radiofrequency thermal rhizotomy. *J Neurosurg* 83:989-993, 1995.
76. Tan LK, Robinson SN, Chatterjee S: Glycerol versus radiofrequency rhizotomy: A comparison of their efficacy in the treatment of trigeminal neuralgia. *Br J Neurosurg* 9:165-169, 1995.
77. Tator CH, Rowed DW: Fluoroscopy of foramen ovale as an aid to thermocoagulation of the gasserian ganglion. *J Neurosurg* 44: 254-257, 1976.
78. Tekkök IH, Brown JA: The neurosurgical management of trigeminal neuralgia. *Neurosurg Q* 6:89-107, 1996.
79. Tew JM Jr, Keller JT: The treatment of trigeminal neuralgia by percutaneous radiofrequency technique. *Clin Neurosurg* 24:557-578, 1977.
80. Tew JM Jr, Taha JM: Percutaneous rhizotomy in the treatment of intractable facial pain (trigeminal, glossopharyngeal, and vagal nerves), in Schmidek HH, Sweet WH (eds): *Operative Neurosurgical Techniques: Indications, Methods, and Results*. Philadelphia, W.B. Saunders Co., 1995, ed 3, pp 1469-1484.
81. Tobler WD, Tew JM Jr, Cosman E, Keller JT, Quallen B: Improved outcome in the treatment of trigeminal neuralgia by percutaneous stereotactic rhizotomy with a new, curved tip electrode. *Neurosurgery* 12:313-317, 1983.
82. Uematsu S: Percutaneous electrothermocoagulation of spinal nerve trunk, ganglion and rootlets, in Schmidek HH, Sweet WH (eds): *Operative Neurosurgical Techniques: Indications, Methods, and Results*. New York, Grune & Stratton, 1982, pp 1177-1198.
83. van Loveren H, Tew JM Jr, Keller JT, Nurre MA: A 10-year experience in the treatment of trigeminal neuralgia: Comparison of percutaneous stereotaxic rhizotomy and posterior fossa exploration. *J Neurosurg* 57:757-764, 1982.
84. Wilkins RH: Historical perspectives, in Rovit RL, Murali R, Jannetta PJ (eds): *Trigeminal Neuralgia*. Baltimore, William & Wilkins, 1990, pp 1-25.
85. Yoshimasu F, Kurland LT, Elveback LR: Tic douloureux in Rochester, Minnesota 1945-1969. *Neurology* 22:952-956, 1972.
86. Young RF: Glycerol rhizolysis for treatment of trigeminal neuralgia. *J Neurosurg* 69:39-45, 1988.
87. Young RF, Vermeulen SS, Grimm P, Blasko J, Posewitz A: Gamma knife radiosurgery for treatment of trigeminal neuralgia: Idiopathic and tumor related. *Neurology* 48:608-614, 1997.
88. Young RF, Vermeulen S, Posewitz A: Gamma knife radiosurgery for treatment of trigeminal neuralgia. *Stereotact Funct Neurosurg* 70[Suppl 1]:192-199, 1998.
89. Zhang KW, Zhao YH, Shun ZT, Li P: Microvascular decompression by retrosigmoid approach for trigeminal neuralgia: Experience in 200 patients. *Ann Otol Rhinol Laryngol* 99:129-130, 1990.

## COMMENTS

The authors have treated a large series of patients and have provided a very carefully documented analysis of their closely followed patients' experiences and outcomes. The real-world results presented here can be accomplished by experienced and conscientious neurosurgeons in applying this technique to patients with idiopathic trigeminal neuralgia (ITN).

Radiofrequency (RF) lesioning of the trigeminal nerve has stood the test of time as an effective treatment for this problem. There is and always will be a down side to this procedure, particularly in the form of dysesthetic sequelae such as anesthesia dolorosa and corneal anesthesia, because this technique is destructive. By applying careful attention to detail and performing minimally destructive procedures, Kanpolat et al. have demonstrated that these complications can be kept to a minimum, which should be acceptable for many patients who are not good candidates for a more invasive microvascular decompression procedure.

Although the preference at my institution is to use glycerol neurolysis as our percutaneous procedure of choice because it produces comparable results and does not require as much patient cooperation, both techniques are very acceptable alternatives as long as the RF lesioning is performed as described here to make it a minimally destructive technique and to minimize the dysesthetic sequelae.

**Ronald I. Apfelbaum**  
Salt Lake City, Utah

Kanpolat et al. have defined their results in an enormous group of patients who underwent percutaneous RF trigeminal rhizotomy (RF-TR) for ITN during a 25-year period. Undoubtedly, their technique and experience evolved, and they have now settled on a stable management strategy. Although they often resort to RF-TR in patients older than 50 years of age, clearly other options, including microvascular decompression

sion, will be considered at many centers. The value of microvascular decompression lies in its potential treatment of the etiology rather than the symptoms of the disorder, unlike other treatments. This article is remarkable for its report of a low complication rate, the absence of any operative mortality (which is very surprising in a group of patients who often have associated blood pressure or cardiac difficulties), and the ability to determine long-term outcomes in a group of patients who had a single procedure. It is clear that, over time, 58% of patients maintained complete pain relief 5 years after the procedure, 52% had complete pain relief after 10 years, and 41% had complete pain relief after 20 years. Pain relief can be reestablished in many patients by repeating the procedure, so knowing the number of such procedures necessary in the entire group reported here would be valuable. The authors are correct to emphasize the ability to repeat such procedures so that with initial management, limited lesions that are carefully titrated for the area of pain involved are entirely appropriate. Prevention of complications is extremely important because trigeminal neuralgia (TN) itself is eminently treatable, but deafferentation pain (as a side effect of destruction of the trigeminal system) is virtually untreatable. An ounce of prevention is worth a pound of cure. The authors have been diligent in pursuing long-term follow-up of this series of patients. TN, as a subjective disorder, is very often difficult to "nail down" because patients may have no pain, slight pain, or moderate pain from one day to another, and their degree of pain waxes and wanes during the course of days, weeks, or years.

**L. Dade Lunsford**  
*Pittsburgh, Pennsylvania*

This article is important because it offers, with a large series and good follow-up, further evidence of the efficacy and safety of the RF-TR procedure for ITN, provided that the procedure is performed properly. It emphasizes several fundamental truths about the RF-TR procedure that are not appreciated by all neurosurgeons. First, the patient must be awake and responsive during lesioning so that the surgeon can monitor the procedure. Second, the mainstay of final localization is a low voltage threshold to stimulation. Third, the RF-TR technique provides greater control of the site and of the degree of sensory deficit produced. Fourth, recurrence of pain requires merely another outpatient treatment. Fifth, bilateral tic can be treated safely and adequately with the RF-TR technique. Sixth, loss of the motor root is no problem and often is not even apparent to the patient. In addition, it is important that the results reported here are based on the follow-up responses of the patients and not on the authors' own evaluation.

The authors state that Fothergill published the first scientific article on TN in 1773, but actually there were reports before then. The first complete publication of a case of TN is found in a book on diseases of the head by Dr. Johann Wepfer in 1727, and Nicholas Andre described two cases of true TN in 1732 (5). The authors also state that their series presents the longest follow-up (5.7 yr) of any large series of patients with

TN. Actually, the series that I published in 1991 had an average follow-up period of 9.2 years (1).

Some variations in technique are pertinent to this article. With the technique the authors describe, the patient is not anesthetized while the needle is passed through the foramen ovale, the most painful part of the procedure. I formerly used only fentanyl and droperidol for this part of the procedure but then altered the technique to use methohexital (Brevital) anesthesia before passing the needle through the foramen. Among those patients who had been treated by the first technique, after they were anesthetized with Brevital while being treated for a recurrence, the universal response, "Dr. Nugent, you sure have improved the way you do this operation," indicated that it provided better pain relief. Brevital does not interfere with good postlesion testing and is a better agent than propofol.

A further firm observation and conviction at my institution is that instead of using the lateral x-ray for localization of the electrode as the authors describe, the anteroposterior view projected down the orbitomeatal line provides much more accurate localization of the electrode in the retrogasserian rootlets. I believe that with a smaller, cordotomy-type electrode, their incidence of cranial nerve paralysis and loss of the corneal reflex (5.7%) could be reduced (2).

Although the authors emphasize that their RF-TR technique provides better control of the lesion, and with that I agree, it is not clear what they mean by "control." To me, control means being able not only to control the location and extent of sensory deficit but also to limit the lesion and sensory deficit to the second division when only that division is involved. At my institution, we have been able to all of these goals 74% of the time with the cordotomy-type electrode. In satisfactorily treating first-division pain by partially treating this division but preserving some corneal sensation, we have been successful in 91% of cases with first-division triggering. The constant monitoring of the ciliary reflex (direct and consensual blink reflex when the eyelashes are flicked with a corner of facial tissue) during first division lesioning is imperative when treating this division. The authors recommend glycerol for first-division pain, but the smaller electrode permits treatment of this division with safety. My institution does not hesitate to treat first-division tic with RF.

Some interesting results in this article are at variance with other reports. The authors found an extremely low incidence (4.1%) of postoperative masseter weakness, whereas Taha et al. (4), using the same type of electrode in a large series, found a 23% incidence of masseter weakness. This latter incidence is more in keeping with the findings in the literature. My own study results indicate a 26% incidence of masseter weakness. Also, these authors' finding regarding a 1% incidence of "painful dysesthesia" is far lower than and not consistent with findings in other large series in which the average incidence of "annoying dysesthesias" is closer to 5 to 8%. Their technique includes nothing magical that would explain their results.

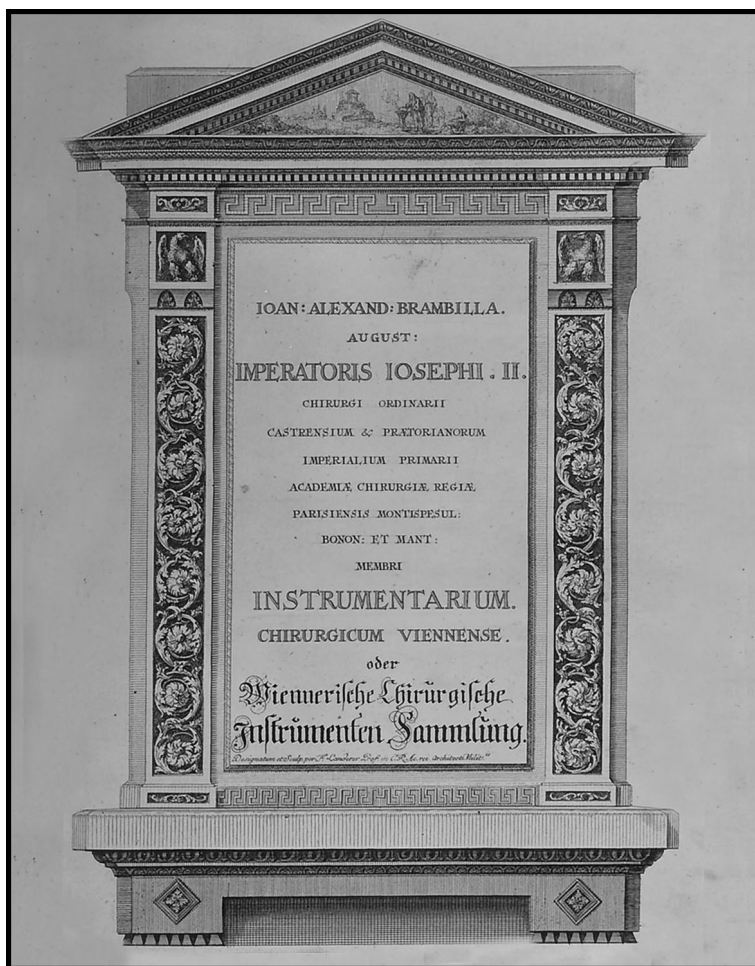I believe that these authors should have made some mention of the feared complication of hypertensive intracerebral hematoma that has been described in connection with this

procedure and also of the need for constant monitoring of the patient's blood pressure (3). The authors checked their patients' blood pressure only every 5 minutes during the RF-TR procedure, but more constant monitoring is recommended, especially in procedures involving an approach through the foramen ovale and the creation of lesions.

The article would have been improved if the authors had defined the end point of their patients' sensory deficits. How much sensory deficit was produced? Less is better than more in most cases. It is remarkable that in treating most patients adequately, only a mild amount of sensory deficit results. Use of hypalgesia leads to a happier patient than use of analgesia does. Also, with this treatment, because there is a spectrum of "annoying dysesthesias" that runs from mild to severe, a more quantitative definition of these sensations than "painful dysesthesia," the term used here, would have been helpful.

**G. Robert Nugent**  
Morgantown, West Virginia

1. Nugent GR: Surgical treatment: Radiofrequency gangliolysis and rhizotomy, in Fromm GH, Sessle BJ (eds): *Trigeminal Neuralgia: Current Concepts Regarding Pathogenesis and Treatment*. London, Butterworth-Heinemann, 1991, pp 159-184.
2. Nugent GR: Radiofrequency treatment of trigeminal neuralgia using a cordotomy-type electrode. *Neurosurg Clin N Am* 8:41-52, 1997.
3. Sweet WH, Poletti CE, Roberts JT: Dangerous rises in blood pressure upon heating of trigeminal rootlets: Increased bleeding times in patients with trigeminal neuralgia. *Neurosurgery* 17:843-844, 1985.
4. Taha JM, Tew JM Jr, Buncher CR: A prospective 15-year follow up of 154 consecutive patients with trigeminal neuralgia treated by percutaneous stereotactic radiofrequency thermal rhizotomy. *J Neurosurg* 83:989-993, 1995.
5. Wilkins RH: Historical perspectives, in Rovit RL, Murali R, Jannetta PJ (eds): *Trigeminal Neuralgia*. Baltimore, Williams & Wilkins, 1990, pp 1-26.



Frontispiece to Giovanni Alessandro Brambilla's (1728-1800) *Instrumentarium chirurgicum Viennense; oder, Wienerische chirurgische Instrumenten Sammlung*. Vienna, Matthias Andreas Schmidt, 1781. (Also see pages 475, 597, 635, and 672. Courtesy, Rare Book Room, Norris Medical Library, Keck School of Medicine, University of Southern California, Los Angeles, California.)